



**INTERNATIONAL JOURNAL OF ENGINEERING SCIENCES & RESEARCH
TECHNOLOGY**

RETINAL IMAGE PROCESSING FOR DIABETIC RETINOPATHY

Prof.R.S.Shriwas*, Sumit G Dhamodikar

* Dept of EXTC, J.D.I.E.T Ytl
Dept of EXTC, J.D.I.E.T Ytl

ABSTRACT

The Diabetic Retinopathy consists of lesions characteristic group extracted from the retinal image of individual person had diabetes for several years. It aims to present the different techniques for automatic localization of different retinal features as well as lesions. It presents various methods which are used in identifying macular edema. The detection of macular edema assists ophthalmologists in order to apply proper treatments which resulted into the elimination of disease completely or minimize its severity.

The World Health Organization (WHO) overall in world, there are about 135 million people have diabetes mellitus. And this number may increase up to 300 million by 2025. The analysis of medical image is growing research area which attracts number of researcher's interests for new methods.

KEYWORDS: Retinal image processing.

INTRODUCTION

The major cause of blindness in working age population is Diabetic Retinopathy. The report of International Diabetes Federation states that that over 50 million people in India have the disease of diabetic retinopathy and it is increasing rapidly day by day. It is estimated that there are 135 million people suffering from diabetes mellitus and this number will increase to 300 million upto 2025 as per the World Health Organization. The early detection as well as treatment of diabetic retinopathy diseases is important for avoiding problem related to vision loss [1].The commonest cause of blindness in the working age group in the developed world is diabetes .The diabetes affects patient's sight which causes cataracts and glaucoma. It also damages to blood vessels inside the eye; this condition is known as "diabetic retinopathy."

Diabetes is one of the fastly increasing health problems worldwide. Only in Finland, there are 30,000 people diagnosed to the maturity onset diabetes in case of youth, while this figure is reached to 200,000 people in adults [2]. In addition, as per the current estimate, this predicts that there are 50,000 patients which are since undiagnosed. The proper detection and early treatment of diabetes is used to save much amount because the implications of the late treatment

and improper or poor treatment are much more costly [3].

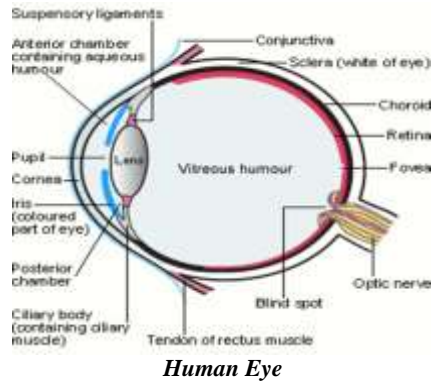
Digital image processing is applied to the field of medical diagnosis for reducing the time and stress which is undergone by the ophthalmologist for diagnosis and treatment of diabetic retinopathy. Digital image processing determines the presence of NPDR and PDR. Otherwise it applies techniques of digital image processing on fundus images. The fundus images are taken with the use of medical image camera captured by a medical staff in the respective hospital [4].

BASICS DIABETIC RETINOPATHY

Human Eye Structure

Light enters the eye through the pupil then it is focused on the retina. The lens helps in focusing images from different distance. The iris controls the amount of light entering the eye, as the intensity of light increases iris closes when light intensity decreases iris opens.

Figure:



Human Eye

Diabetic Retinopathy

Diabetic retinopathy is light sensitive inner layer of the eye retina which is caused by damage to blood vessels. There are mainly two types of diabetic retinopathy they are non-proliferative and proliferative. The Non proliferative diabetic retinopathy is the early stages of the disease. It fevers blood vessels in the eye retina which leads to blurred vision for fluid leaks. Proliferative retinopathy disease is more serious and more advanced and they are the new blood vessels in the eye of human.

Proliferative diabetic retinopathy (PDR)

The main reason for Proliferative diabetic retinopathy (PDR) is when many of the blood vessels in the retina close; it prevents enough blood flow which is required for flowing. Then as an attempt for supply blood to the area where the original vessels closed; retina responds this by growing new blood vessels which is called neovascularization. The new blood vessels formed are abnormal .So they become unable to supply the proper blood flow to the retina. Thus the new vessels formed are also often accompanied by scar tissue .It may cause the retina to wrinkle or detach. The more severe vision loss is seen in the PDR than NPDR as it is responsible for affecting both central and peripheral vision. Following are some ways by which PDR affects vision. When many of the blood vessels in the retina close to each other it results in Proliferative diabetic retinopathy (PDR) which prevents enough blood flow. Thus for supplying blood as an attempt to the area where the original vessels is closed that time retina responds by growing new blood vessels which is known as neovascularization. The formed new blood vessels are abnormal and unable to supply proper blood flow to the retina. The PDR can affect both central and peripheral vision.

Non proliferative Diabetic Retinopathy

Non-proliferative diabetic retinopathy (NPDR) is the earliest stage of diabetic retinopathy. In the early stage

damage blood vessels in the retina starts to leak extra fluid .It also leaks small amounts of blood into the eye. Some of the times; deposits of cholesterol or other fats from the blood may leak into the retina.

The NPDR can cause changes in the eye; includes little bulges in blood vessels of the retina that often leak fluid called micro aneurysms. Retinal hemorrhages means small spots of blood that leak into the retina. Hard exudates collects of cholesterol or other fats from the blood that have leak retina. Macular edema is the swelling and thickening of the macula caused by fluid leaking from the retina's blood vessels. When macula is swollen it does not function properly. The Macular edema is the more common cause of vision loss in diabetes. Macular ischemia is small blood vessels (capillaries) close. Thus most of the times vision blurs because the macula is unable to receive enough blood for working properly. It is mostly observed that several diabetic patients have mild NPDR; but usually it does not affect their vision. And so if the vision is affected it can be said that patient is suffering from macular edema and macular ischemia.

Overview of Diabetic Retinopathy Detection

Automated diabetic retinopathy detection may be considered as computer vision problem. The extraction of retinal lesions such as micro aneurysms, hemorrhages, exudates is included in automated diabetic retinopathy. Some challenges are faced by the accurate detection of these features .They are as follows:

1. Similarity of retinal lesions to the landmark features like as blood vessels, optic disc and the macula (fovea).
2. Variation in illumination and Changes in contrast across the image.

Thus Preprocessing is useful for tackling of this problem. In some images very little color differences is executed by hemorrhages and exudates, for fulfilling such demands robust color normalization techniques is mostly used. Following are some of the important steps in the detection and severity classification process:

1. Pre-processing for contrast enhancement and removal of noise
2. Detection, Localization of the Optic Disc and its segmentation
3. Retinal vascular tree segmentation
4. Localization of fovea region
5. Abnormal Feature Extraction
6. Classification of different stages of Diabetic Retinopathy
7. Evaluation of the performance of classifier.

Preprocessing

The main aim of preprocessing methods is to achieve image normalization. This is achieved by attenuation of intensity variations in the input images. The original images contain non-uniform spatial variations across the image. Many models have been developed for attenuation of such variations. Adaptive contrast enhancement techniques, mathematical model representation of the non-uniformity of the image and image filtering techniques are some of the techniques developed. Correction methods for non-uniform illumination. Subtracting the non-uniform component of the image from the original image which gives rise to filter the variations. Several approaches assume that the image consists of foreground and background components. Retinal vasculature, lesions and the optic disc constitute the foreground. While the remaining features consist of the background. A shade correction algorithm generates background approximation by using mean filtering. Then after that original green channel image is either subtracted or divided by the background for achieving shade correction.

As color is one of the important features for differentiating different lesions, normalization of color descriptor is very important for minimizing the color variations in the images. The approach to reduce the variations is histogram equalization. This variation is carried out by redistribution of the gray levels for achieving uniform distribution of pixel intensities. One of the methods is Contrast enhancement which enhances the contrast of the image and they are usually applied on the low contrast images.

Localization of the Optic Disc and Segmentation of the Disc

Localizing the disc and segmentation of the optic disc is essential as far as differentiation of the exudates from the optic disc. The process consists of finding approximate optic disc center. The problem is the distraction which is caused by other larger lesions like exudates.

Detection of Fovea

The darkest region in the retina is the Fovea and its color is same as that of blood vessels and micro aneurysms and hemorrhages. Therefore the fovea must be localized and detected.

Segmentation of Retinal Blood Vessels

Morphological operators and edge detection are used for doing retinal vasculature segmentation. The matched filter approach is an improvement over the

Sobel edge operators as well as morphological operators. Along with the Vessel segmentation using mathematical morphology, a curvature evaluation method provides better results than the results provided by matched filters. Supervised classification approaches with the use of neural networks are based on pixel classification. In this approach a pixel feature vector is constructed for each pixel so as to classify the pixel to be belonging to vessel or non-vessel. PCA, Gabor filters and Bayesian classifiers techniques are used in supervised classification.

Feature Extraction for Diabetic Retinopathy

After the optic disc, fovea and blood vessel network localization, the exudates, hemorrhages and micro aneurysms are taken out from the images.

Micro aneurysms and hemorrhages detection

The removal of other brighter regions such as exudates and optic disc are required to detect these dark red regions. Morphological operations using a structuring element, top-hat transformation were the methods used initially. Provided a sensitivity of 77.5% and specificity of 88.7% is provided by Recursive region growing methods with the moat operator.

Detection of hard Exudates and cotton wool spots

Exudates formed due to lipid, protein which is accumulated over the retina and which is brightly colored. Thus, the other brighter regions like as blood vessel network and the optic disc should be removed before extracting exudates. Recursive Region growing algorithms assume pixel adjacency in terms of similarity in gray levels were used for detection of the boundary of a region [5].

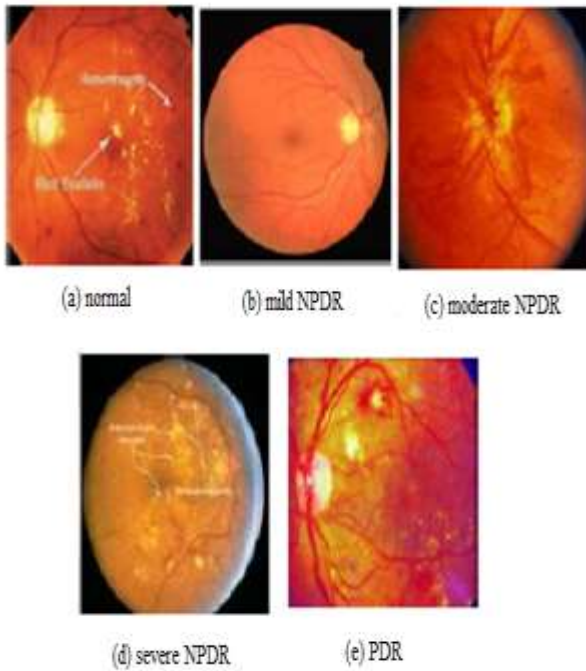
Texture information

Texture provides a measure of properties of an image, as smooth, coarse or regular with the uniform variation of pixel intensities. Structural, statistical and spectral are the three ways used for measuring the texture. A statistical method employs the spatial relationship between the pixels intensities. Measures like as entropy, contrast, homogeneity, correlation, and energy are extracted from the Gray level Co-occurrence matrix.

Classification of Diabetic Retinopathy Severity

In the Mild NPDR stage, at least one micro aneurysm either with or without hemorrhages, exudates might be present. The moderate NPDR consists of large numbers of hemorrhages and micro aneurysms along with the presence of exudates. All four quadrants of

the retina with vascular abnormalities are occupied by micro aneurysms and hemorrhages, in severe retinopathy. In the most of the severe stage called as Proliferative Retinopathy, abnormal as well as new blood vessels grows on retinal surface. The different stages of retinopathy are as shown in the diagram given below.



2.1.7 Evaluation of the Performance of Classifier:

The medical input data is usually classified into two classes in medical diagnosis where the disease is either present or absent. The classification accuracy of the diagnosis is assessed by using the sensitivity and specificity measures. Following are the practices in the medical research, where the fundus images related to the diabetic retinopathy are evaluated by using sensitivity as well as specificity per image basis. Sensitivity is nothing but the percentage of abnormal fundus classified as abnormal, whereas specificity is the percentage of normal fundus classified as normal by the screening. The higher the sensitivity and specificity 3 values, the better the diagnosis. Sensitivity and specificity can be computed as [6]:

$$\text{sensitivity} = \frac{Tp}{Tp+FN}$$

$$\text{Selectivity} = \frac{TN}{TP + FN}$$

where Tp is the number of abnormal fundus images found as abnormal, TN is the number of normal fundus images found as normal, FN is the number of normal

fundus images found as abnormal (false positives) and FN is the number of abnormal fundus images found as normal (false negatives). Sensitivity and specificity are also referred to as the true positive rate (TPR) and true negative rate (TNR), respectively.

DATABASES

RETINAL IMAGE PUBLIC DATABASE

MESSIDOR

The MESSIDOR database has been established for facilitating studies on computer assisted diagnoses of diabetic retinopathy. A total of 1200 eye funds color numerical images of the posterior pole for this database were acquired by 3 ophthalmologic departments. These images are captured using a color video 3CCD camera on a Topcon TRC NW6 non-mydiatric radiograph with a 45 degree field of view [7]. The images were captured using 8 bits per color plane. The pixels are of 1440*960, 2240*1488 or 2304*1536size. Out of total of 1200, 800 images were acquired with pupil dilation that is one drop of Tropic amide at 0.5% and 400 are acquired without dilation [7].

Department of ophthalmologic 1200 images 3 sets are packed into one per each set of 4 zipped TIFF format and sub for each image in an Excel file along with medical diagnosis each set consist of 100 images is divided into[7].

Medical diagnoses: Medical experts provide two diagnoses for every image. The two diagnoses are

1. Retinopathy grade
2. Risk of macular edema

Retinopathy grade

- 0 (Normal): ($\mu A = 0$) AND ($H = 0$)
- 1: ($0 < \mu A \leq 5$) AND ($H = 0$)
- 2: ($(5 < \mu A < 15)$ OR ($0 < H < 5$)) AND ($NV = 0$)
- 3: ($\mu A \geq 15$) OR ($H \geq 5$) OR ($NV = 1$)

μA : number of micro aneurysms

H : number of hemorrhages

$NV = 1$: neo vascularization - $NV = 0$: no neo vascularization

Risk of macular edema

Difficult exudates is used to mark the risk of macular edema

- ★ 0 No risk: Visible hard exudates not found.
- ★ Low difference between macula & hard exudates > one papilla diameter

- ★ 2: limited space between macula & hard exudates
 <= one papilla diameter

All the images contained in the database are used for making actual clinical diagnoses of patient.

DRIVE (Digital Retinal Images for Vessel Extraction):

The main reason for has been establishment of DRIVE database is for enabling comparative studies on segmentation of blood vessels in retinal images. Test the database research community on their algorithms and results through this Web site [8] other researchers invited to share with the drive of the diabetic retinopathy screening photos database program was obtained in the Netherlands. Screening the population of the person who are aged between 25-90, 400 diabetic subjects. Forty photographs randomly selected Show no signs of diabetic retinopathy, 33 and 7 light show signs of early diabetic retinopathy in a person. Each image has been JPEG compressed [8]. The images acquired by using a Canon CR5 non mydriatic 3CCD camera with a 45 degree field of view (FOV). Each image was captured using 8 bits per color plane .Its dimension is 768 by 584 pixels. FOV is approximately 540 pixels of each image and having a diameter of the FOV cropped around the images to the database. For each image, a mask image provided that delineates FOV [8].

STARE Dataset: Gaze (retinal structural analysis) project conceived and Michael Goldbaum, MD of University of California, San Diego in 1975. It was launched in U.S. and fund was provided by the national institutes of health. Its history, More than thirty people with backgrounds ranges from engineering to medical science is contributed for this project. Images and clinical data Shiley eye Center at the University of California, San Diego, and the Veterans Administration Medical Center in San Diego provided by [9].

CONCLUSION

The different aspects of diabetic retinopathy detection are explained by using retinal image processing. Introduction to the basic terms and concepts of DR along with the major retinal datasets like as MESSIDOR, DRIVE and STARE. Also include the detection of red spots and bleeding in this work, though more work still need to be done in order to

reduce the error due to over enhancement of noise and misdetection. This is a very good result in the diagnosis process and it shows how far the use of image processing can replace the tedious and strenuous work at our various hospitals.

REFERENCES

1. (IJCSIS) International Journal of Computer Science and Information Security, Vol. 7, No. 1, 2010
2. Gunvor von Wendt. Screening for diabetic retinopathy: Aspects of photographic methods. PhD thesis, KarolinskaInstitutet, 2005.
3. Finnish Diabetes Association. Development programme for the prevention and care of diabetes, 2001. ISBN 952 5301-13-3.
4. AUTOMATIC DIAGNOSIS OF DIABETIC RETINOPATHY USING FUNDUS IMAGES master thesis Blekinge Institute of Technology October 2006
5. Sinthanayothin, C., Boyce, J., Williamson, T., Cook, H., Mensah, E., LaI, S., Usher, D., 2002. Automated detection of diabetic retinopathy on digital fundus images. Diabet. Med. 19,105- 112
6. Niemeijer, M., van Ginneken, B., Russell, R. S., Suttorp-Schulten, S. A. M., and Abramoff, D. M., Automated detection and differentiation of drusen, exudates, and cotton-wool spots in digital color fundus photographs for diabetic retinopathy diagnosis. Invest. Ophthalmol. Vis. Sci. 48(5):2260–2267, 2007.
7. IJRET: International Journal of Research in Engineering and Technology eISSN: 2319-1163 | pISSN: 2321-7308
8. Sinthanayothin, C., Boyce, J., Williamson, T., Cook, H., Mensah, E., LaI, S., Usher, D., 2002. Automated detection of diabetic retinopathy on digital fundus images. Diabet. Med. 19,105- 112
9. Niemeijer, M., van Ginneken, B., Russell, R. S., Suttorp-Schulten, S. A. M., and Abramoff, D. M., Automated detection and differentiation of drusen, exudates, and cotton-wool spots in digital color fundus photographs for diabetic retinopathy diagnosis. Invest. Ophthalmol. Vis. Sci. 48(5):2260–2267, 2007.